

Received: 2008.01.15  
Accepted: 2008.04.07  
Published: 2010.02.01

**Authors' Contribution:**

- A** Study Design
- B** Data Collection
- C** Statistical Analysis
- D** Data Interpretation
- E** Manuscript Preparation
- F** Literature Search
- G** Funds Collection

## "Sleeping Beauty paraphilia": Deviant desire in the context of bodily self-image disturbance in a patient with a fronto-parietal traumatic brain injury

Francesco Bianchi-Demicheli<sup>1ABCDEF</sup>, Christian Rollini<sup>1BE</sup>, Karl Lovblad<sup>2BE</sup>,  
Stephanie Ortigue<sup>3ABCDEF</sup>

<sup>1</sup> Psychosomatic Gynaecology and Sexology Unit, Emergency and Liaison Services, Geneva University Psychiatric Center, Switzerland

<sup>2</sup> Division of Neuroradiology, Radiology Department, Geneva University Hospital, Switzerland

<sup>3</sup> Department of Psychology, Syracuse University, Syracuse, New York, U.S.A.

**Source of support:** Departmental sources

### Summary

**Background:**

Several case series and reports describe paraphilia as occurring after brain damage, mostly in the frontal lobes and diencephalic structures. Hypersexuality and paraphilic behaviors are also documented in a variety of other neurologic disorders, (e.g., Kluver Bucy syndrome, and more rarely in multiple sclerosis). In multiple sclerosis, hypersexual behavior and paraphilias have been associated with various focal brain lesions in the frontal and temporal lesions when inflammatory demyelination involves the hypothalamus and septal regions.

**Case Report:**

A case of a patient who developed a particular and progressive sexual deviant behaviour after a head trauma. This men felt sexually aroused from seeing sleeping women as well as from taking care of their hands and nails while they were asleep. The patient was diagnosed with a moderate dysexecutive syndrome characteristic of a frontal disorder and a very specific parietal-related bodily self image disorder characterized by an incomplete mental image of his hands. The clinical hypothesis was that the paraphilia might be related to his post-traumatic disturbed bodily self image and more specifically to its related impulsive needs to complete his hands representation.

**Conclusions:**

This case report highlights the potential link between paraphilia, deviant and aggressive sexual behaviour, neurological disturbance and self-representation. The treatment of paraphilias remains very complex, and requires taking into account not only the social and psychological aspects of the disease, but also its organic dimensions.

**key words:**

**paraphilia • body image disturbance • sex offenders • sexual deviant behaviour • self representation • desire • intention**

**Full-text PDF:**

<http://www.medscimonit.com/fulltxt.php?ICID=878344>

**Word count:**

981

**Tables:**

–

**Figures:**

1

**References:**

15

**Author's address:**

Francesco Bianchi-Demicheli, Psychosomatic Gynaecology and Sexology Unit, Emergency and Liaison Services, Geneva University Psychiatric Centre, 15 rue des Pitons, 1205 Geneva, Switzerland, e-mail: francesco.bianchi-demicheli@hcuge.ch

## BACKGROUND

Paraphilias are defined as recurrent, and intense sexual urges, fantasies, or behaviors that involve unusual objects, activities, or situations and cause clinically significant distress or impairment in social, occupational, or other important areas of functioning [1]. The major categories of paraphilias in DSM-IV are fetishism, frotteurism, exhibitionism, pedophilia, sexual masochism, sexual sadism, transvestic fetishism, voyeurism, and also a separate category for other paraphilias not otherwise specified, such as zoophilia. Recurrent and intense sexually arousing urges, fantasies, and behaviors have to occur for at least 6 months [1].

There have been several case series and reports of paraphilia occurring after brain damage [2–4]. More critically, idiopathic paraphilias almost always begin in childhood adolescence, or early adulthood, and rarely occur with new onset after the age of 30 years, while acquired paraphilias are often associated with focal brain injury [5]. Although, brain damage is most frequently associated with hyposexuality, sometimes hypersexuality and atypical sexual interests may be present, especially after a traumatic frontal brain injury [2,4,6,7]. Hypersexuality and deviant behavior (e.g., paraphilia, sexual offenses) are associated with several focal brain lesions, especially those that involve loss of integrity of the frontal lobes and diencephalic structures. In a recent study, Walter et al. tested 13 pedophilic patients and 14 healthy control subjects during visual stimulation with emotional and erotic pictures with functional magnetic resonance imaging (fMRI) [11]. Walter et al. observed differential activations during the erotic condition comprised the hypothalamus, the periaqueductal gray, and dorsolateral prefrontal cortex. Alterations of emotional processing concerned the amygdala-hippocampus and dorsomedial prefrontal cortex [10]. Hypersexuality and paraphilic behaviors are also documented in a variety of other neurologic disorders, (e.g., Kluver Bucy syndrome, and more rarely in multiple sclerosis). In multiple sclerosis, hypersexual behavior and paraphilias are distinctly uncommon in this population of patients, but have been associated with various focal brain lesions in the frontal and temporal lesions when inflammatory demyelination involves the hypothalamus and septal regions [9,10]. In a sample of 476 male paraphilics and sex offenders Langevin found that 49.3% of them had sustained head injuries that led to unconsciousness and of these 22.5% sustained significant neurological insults [8]. Although neuroimaging data about paraphilics and sex offenders are limited and with methodological limits, the most frequent finding involves verbal deficits and other manifestations of left fronto-temporal anomalies [4].

## CASE REPORT

In February 2007, a married 34-year-old man consulted to emergency psychiatric unit after a physical aggression against his wife.

His marriage had been in crisis for several years because over the time the patient developed a particular and progressive sexual deviant behaviour. He felt sexually aroused from seeing sleeping women as well as from taking care of their hands and nails while they were asleep, beginning mostly with the right hand.

In the first time of his marriage he could control these fantasies, but over the years he lost the control of his sexual urges and he must irresistibly act his deviant behaviour. In order to realize his uncontrollable impulse, he was used to provide his wife sleeping pills to satisfy his paraphilia. In the first time his wife used to agree to take sleeping pills, but later she refused to bend to man's freakish will. The man began secretly to administer benzodiazepines since the dosage of 23 mg of Bromazepam.

In September 2006, his wife discovered this practice and refused to take sleeping pills and the couple entered in a very strong conflict.

Because of the extremely powerful obsession with sleeping women and painting their nails, the patient disguised himself with a latex mask and attacked his wife, as she returned from work, with an Olerosin Capsicum (OC) spray, to anaesthetize her. During this episode, his wife succeeded in taking off his mask, escaped and called the police who brought him to the psychiatric emergencies.

The psychiatric exam was normal as well as the routine laboratory tests. The patient did not take medications and did not have a family history of medical illness.

However in the patient history was found an episode of head trauma at the age of 10 years with a four days post-traumatic coma.

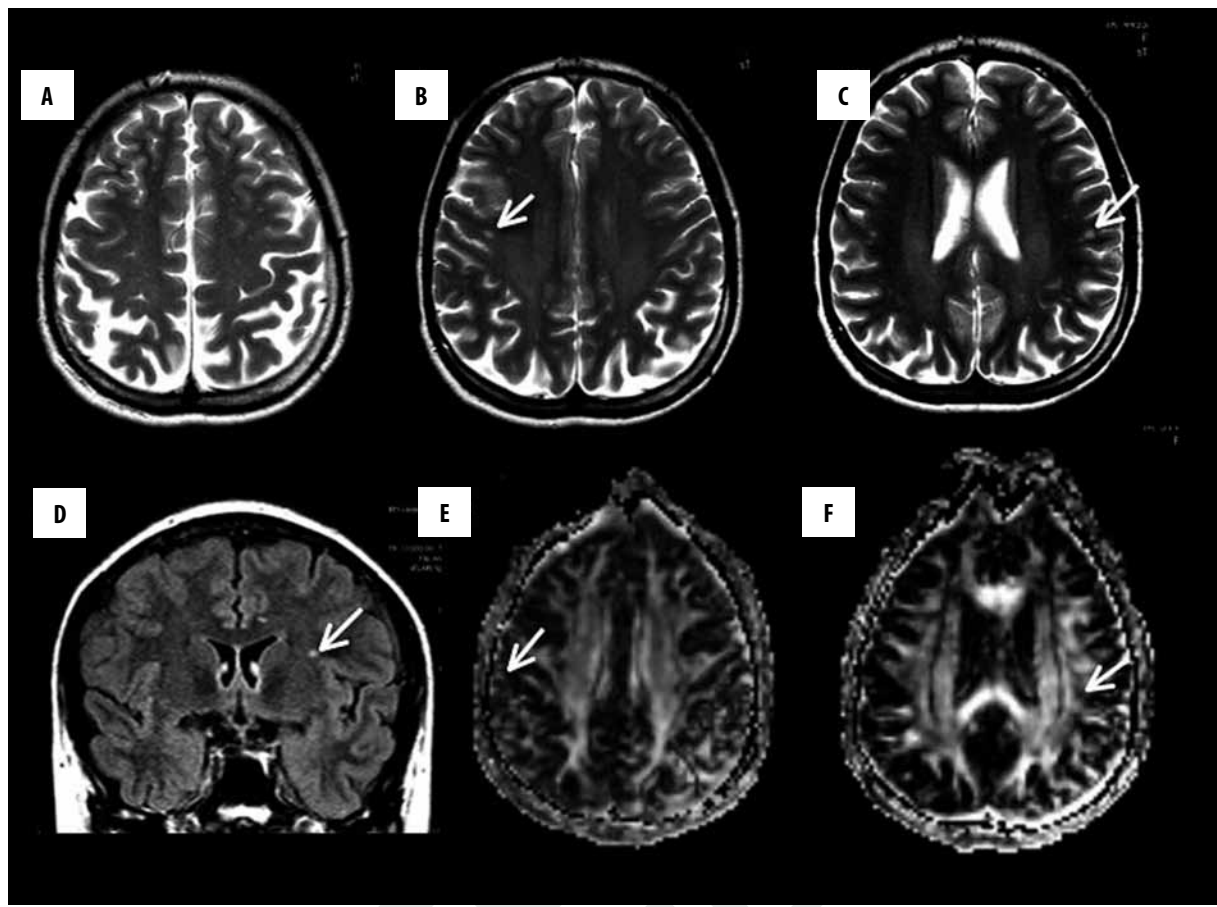
In order to explain this unknown form of paraphilia and bizarre sexual behaviour, he received neurological evaluations, including neuroimaging and neuropsychological exams.

The cerebral MRI showed a moderate atrophy in the fronto-parietal region with a diffuse and severe white matter injury compatible with his previous head trauma (Figure 1). On a functional viewpoint, this brain network is known to sustain among others, the sense of self, body-image, and attention mechanisms. His neuropsychological exam was in line with this assumption. The patient was diagnosed with a moderate dysexecutive syndrome and a very specific body image disorder characterized by an incomplete mental image of his hands, mostly the right (i.e., personal representational hemineglect), as ascertained by his graphical representation of his body parts [12].

The clinical hypothesis was that the paraphilia might be related to his post-traumatic disturbed body image and more specifically to the incomplete hands representation.

## DISCUSSION

In this case report the focal moderate atrophy in the fronto-parietal region, a brain network involve in attention mechanisms, and bodily self representation [12–15], in association with the diffuse and severe white matter injury, might explain the present unusual form of paraphilia that is characterized by being sexually aroused and attracted by the sleeping women (the so-called "sleeping beauty paraphilia"). Although substantial neuropsychiatric morbidity has been identified among persons with paraphilia, we are unaware of previous similar case reports. Presumably, the occurrence of head trauma leading to catatonia in adolescents



**Figure 1.** On the T2 images (A–C: 5 mm thick slices; TR: 4453 ms; TE: 100 ms) one notes atrophy in the parietal and frontal lobes as well as subcortical lesions in the frontal white matter (arrows B,C); FLAIR (5 mm thick slices; TR: 11000; TE: 140ms) also shows multiple subcortical white matter lesions (arrows: D); DTI (5 mm thick slices; TR: 3714 ms; TE: 70) demonstrates a decrease of the fractional anisotropy in the areas seen on the right (E: arrow) and on the left (F: arrow).

might have played a critical role on the development of his sexual self and body image.

This case report highlights the potential link between paraphilia, deviant and aggressive sexual behaviour, neurological disturbance and self-representation.

## CONCLUSIONS

The treatment of paraphilias remains very complex, and requires taking into account the not only social and psychological, but also organic dimensions of disease.

## REFERENCES:

1. American Psychiatric Association: Diagnostic and statistical manual of mental disorders: DSM-IV (4<sup>th</sup> ed., text revision), 2000
2. Lehne GK: Brain damage and paraphilia: treated with medroxyprogesterone acetate. *Behavioral Science*, 2005; 145–58
3. Briken P, Habermann N, Berner W, Hill A: The influence of brain abnormalities on psychosocial development, criminal history and paraphilias in sexual murderers. *J Forensic Sci*, 2005; 50: 1204–8
4. Miller BL, Cummings JL, Mc Intyre H et al: Hypersexuality or altered sexual preference following brain injury. *J Neurol Neurosurg Psychiatry*, 1986; 49(8): 867–73
5. Joyal CC, Black DN, Dassylva B: The neuropsychology and neurology of sexual deviance: a review and pilot study. *Sex Abuse*, 2007; 19(2): 155–73
6. Gautier-Smith PC: Atteinte des fonctions cérébrales et troubles du comportement sexuel. *Revue Neurologique*, 1980; 136: 311–19
7. Bianchi-Demicheli F, Ortigue S: Toward an understanding of the cerebral substrates of woman's orgasm. *Neuropsychologia*, 2007; 45: 2645–59
8. Langevin R: Sexual offenses and traumatic brain injury. *Brain Cogn*, 2006; 60(2): 206–7
9. Huws R, Shubsachs AP, Taylor PJ: Hypersexuality, fetishism and multiple sclerosis. *Br J Psychiatry*, 1991; 158: 280–81
10. Frohman EM, Frohman, Moreault AM: TC-Acquired sexual paraphilia in patients with multiple sclerosis. *Arch Neurol*, 2002; 59(6): 1006–10
11. Walter M, Witzel J, Wiebking C et al: Pedophilia is linked to reduced activation in hypothalamus and lateral prefrontal cortex during visual erotic stimulation. *Biol Psychiatry*, 2007; 62(6): 698–701
12. Ortigue S, Megevand P, Perren F et al: Double dissociation between representational personal and extrapersonal neglect. *Neurology*, 2006; 66(9): 1414–17
13. Blanke O, Ortigue S, Landis T, Seeck M: Stimulating illusory own-body perceptions. *Nature*, 2002; 419(6904): 269–70
14. Ortigue S, Bianchi-Demicheli F: The chronoarchitecture of human sexual desire: a high-density electrical mapping study. *Neuroimage*, 2008; 43(2): 337–45
15. Ortigue S, Bianchi-Demicheli F: Why is your spouse so predictable? Connecting mirror neuron system and self-expansion model of love. *Med Hypotheses*, 2008; 71(6): 941–44.